

# ΤΟ ΒΗΜΑ ΤΟΥ ΑΣΚΛΗΠΙΟΥ

## VEMA OF ASKLIPIOS

OCTOBER-DECEMBER 2002 VOLUME 1 No 4

QUARTERLY EDITION BY THE 1st NURSING DEPARTMENT  
OF ATHENS TECHNOLOGICAL EDUCATIONAL INSTITUTION

Ανακουφιστική φροντίδα σε παιδιά με καρκίνο  
Ανακουφιστική φροντίδα σε ναυτία και έμετο  
Διασχιστική (ψυχογενής) αμνησία  
Η πορεία του Εθνικού Συστήματος Υγείας στην Ελλάδα  
Εφαρμογή πρωτοκόλλου για την αντιμετώπιση  
των κατακλίσεων  
Κακόηθες μελάνωμα στομάχου

Palliative care for children  
Palliative care in nausea and vomiting  
Dissociative (psychogenic) amnesia  
The course of the National Health System in Greece  
The implementation of nursing protocol  
for the management of pressure  
Malignant melanoma of stomach



ΕΝΤΥΠΟ ΚΛΕΙΣΤΟ ΑΡ. ΑΔΕΙΑΣ 1459/99

ΒΗΜΑ ΙΑΤΡΙΚΗΣ ΕΚΔΟΣΕΙΣ

Κατεχάκη &amp; Αδριανείου 3 - 115 25 ΑΘΗΝΑ



## Περιεχόμενα

Από τη σύνταξη 163

### Ανασκοπήσεις

Ανακουφιστική φροντίδα σε παιδιά με καρκίνο.  
Α. Αυγέρης 164

Ανακουφιστική φροντίδα σε ναυτία και έμετο σε  
ασθενείς με νεοπλασματική νόσο. Ε. Θεοδοσο-  
πούλου, Ζ. Τσαμπαλάκη 169

Διασχιστική (ψυχογενής) αμνησία. Κλινική περι-  
γραφή, επιδημιολογία, αιτιολογικές υποθέ-  
σεις, διαγνωστικές-θεραπευτικές προσεγγίσεις.  
Ν. Μόσχος 178

Η πορεία του Εθνικού Συστήματος Υγείας στην  
Ελλάδα από το 19ο αιώνα μέχρι σήμερα και η  
ανάγκη ριζικών θεσμικών αλλαγών στη δομή  
και το ρόλο του. Ε. Λαχανά, Σ. Κοτρώτσιου 186

### Ερευνητική εργασία

Αποτελέσματα εφαρμογής νοσηλευτικού πρωτο-  
κόλλου για την αντιμετώπιση των κατακλίσεων  
στο 251 Γενικό Νοσοκομείο Αεροπορίας. Σ. Δια-  
μάντη, Σ. Μποζώνη, Ε. Αποστολίδη, Α. Σαρπού-  
λου, Ε. Αναστασοπούλου, Μ. Ανδριακοπούλου 194

### Ενδιαφέρουσα περίπτωση

Κακόηθες μελάνωμα στομάχου. Παρουσίαση περι-  
στατικού με άγνωστη πρωτοπαθή εστία. Θ.Γ. Οι-  
κονόμου, Δ. Τσούτσος, Κ. Φραγκιά, Ε. Γκόγκα, Σ.  
Παπαδόπουλος, Β. Γεωργούντζος, Ι. Ιωάννοβιτς 201

Περιεχόμενα τόμου 1 204

Οδηγίες για τους συγγραφείς 207

## Contents

From the editors 163

### Reviews

Palliative care in children with cancer  
A. Avgeris 164

Palliative care of nausea and vomiting in patients  
with cancer. E. Theodosopoulou, Z. Tsabalaki 169

Dissociative (psychogenic) amnesia. Clinical de-  
scription, epidemiology, etiological hypothe-  
ses, diagnostical-therapeutical approaches. N.  
Moschos 178

The course of the National Health System in  
Greece from the 19th century until today and the  
necessity for radical statutorial modifications in  
this structure and its role. E. Lachana, S. Kotrotsiou 186

### Original paper

The outcomes of implementation of nursing pro-  
tocol for pressure ulcers management in 251  
Hellenic Air Force hospital. S. Diamanti, S. Bozoni,  
E. Apostolidi, A. Saropoulou, E. Anastasopoulou, M.  
Andriakopoulou 194

### Case report

Malignant melanoma of the stomach. Report of a  
case presenting with unknown primary lesion.  
T.G. Ionomou, D. Tsoutsos, K. Frangia, H. Gogas, S.  
Papadopoulos, V. Georgountzos, J. Ioannovich 201

Contents of volume 1 204

Instructions to authors 207

# Malignant melanoma of the stomach

## Report of a case presenting with unknown primary lesion

T.G. Iconomou,  
D. Tsoutsos,  
K. Frangia,  
H. Gogas,  
S. Papadopoulos,  
V. Georgountzos,  
J. Ioannovich

Department of Plastic Surgery,  
Microsurgery and Burn Unit,  
"G. Gennimatas", General State Hospital  
of Athens, Athens, Greece

**Key words:** Malignant melanoma, stomach, endoscopy

**Λέξεις κλειδιά:** Κακόηθες μελάνωμα, στομάχος, ενδοσκόπηση

**Abstract** Although the gastrointestinal tract seems to be a common site for melanoma metastases it is extremely unlikely that a melanoma of the gastric mucosa is of primary origin. Only few cases have been reported in the literature and the diagnosis was made clinically, endoscopically or by postmortem material. Moreover, most of the patients had visceral metastases in other areas. A case of malignant melanoma of the stomach diagnosed endoscopically is presented. It was confirmed histologically without any other detectable primary lesion.

**Περίληψη** Κακόηθες μελάνωμα στομάχου. Παρουσίαση περιστατικού με άγνωστη πρωτοπαθή εστία. Θ.Γ. Οικονόμου, Δ. Τσούτσος, Κ. Φραγκιά, Ε. Γκόγκα, Σ. Παπαδόπουλος, Β. Γεωργούντζος, Ι. Ιωάννοβιτς. Τμήμα Πλαστικής Χειρουργικής Μικροχειρουργικής και Κέντρου Εγκαυμάτων, ΠΓΝΑ «Γ. Γεννηματάς», Αθήνα. Το Βήμα του Ασκληπιού 2002, 1(4):201-203. Το κακόηθες μελάνωμα μεθίσταται σε όλα τα όργανα του ανθρωπίνου σώματος, με ιδιαίτερη προτίμηση στο γαστρεντερικό σωλήνα. Έχει αναφερθεί ότι η πιο συχνή εντόπιση μεταστάσεων του γαστρεντερικού είναι το λεπτό έντερο και ακολουθεί ο στόμαχος. Όμως το πρωτοπαθές μελάνωμα στομάχου είναι εξαιρετικά σπάνιο και στη διεθνή βιβλιογραφία έχουν αναφερθεί πολύ λίγα περιστατικά. Παρουσιάζουμε τη σπάνια περίπτωση γυναίκας ασθενούς, ηλικίας 50 ετών, στην οποία διαγνώσθηκε κακόηθες μελάνωμα στομάχου. Η διάγνωση έγινε ενδοσκοπικά με τη λήψη πολλαπλών βιοψιών. Περαιτέρω κλινικοεργαστηριακός έλεγχος δεν εντόπισε πιθανή πρωτοπαθή εστία του μελανώματος. Αναφέρονται και συζητώνται η κλινική πορεία και η αντιμετώπιση της ασθενούς.

Melanoma is reported to metastasize to all organs in the human body.<sup>1</sup> Although it is common for it to metastasize to the gastrointestinal tract, melanoma located primarily in the gastric mucosa is an uncommon tumor.<sup>2-5</sup>

Gastrointestinal metastases are rarely diagnosed before death, with radiologic and endoscopic techniques.<sup>6-8</sup> Most of the cases reported were first diagnosed at postmortem examination. The median survival time for melanoma patients presenting with gastrointestinal invasion is less than a year.<sup>9</sup>

The prolonged survival time reported in a few patients with gastrointestinal metastases, is associated with aggressive surgical treatment, adjuvant chemotherapy and immunotherapy.<sup>10,4</sup> The high mortality rate observed in these patients is associated with multiple metastases to other organs, such as lungs, liver, pancreas, spleen, endocrine glands and brain.<sup>1</sup>

The clinical course and treatment of a woman with melanoma of the stomach, without any other detectable primary lesion, is presented and discussed.

### Case report

A 50-year old woman, previously healthy, presented to our Department on August 2001. She had a palpable mass in the right inguinal region. C-T scan of the upper and lower abdomen did not show the presence of an intra-abdominal mass or disease. Thorough clinical examination of the external genital organs of the patient was negative for findings. The patient underwent a right lymph node inguinal dissection and the pathology showed lymph node metastases of malignant melanoma.

Despite a thorough investigation of each melanocyte-containing tissue and a whole body survey of the patient, no primary lesion was found and the diagnosis of a metastatic malignant melanoma of an unknown primary origin was established.

After the lymph node dissection, high doses IV interferon therapy were given and the patient was subsequently followed up at our melanoma clinic. Two months later she developed a palpable mass in the left inguinal region and she underwent a

Correspondence: T.G. Iconomou, 11 Ioanninon street,  
GR-152 37 Filothei, Athens, Greece  
e-mail: rodolaki@hol.gr

left lymph node inguinal dissection. The pathology report was negative for malignant melanoma metastases.

Two months later the patient complained of epigastric pain, postprandial dyspepsia with gastric heaviness, loss of appetite and loss of weight. Direct gastric endoscopy showed a submucosal gastric mass in the greater curvature of the body of the stomach (fig. 1). The rest of the stomach, the esophagus and the duodenal bulb were normal. Biopsies taken from the mass confirmed the diagnosis of a malignant melanoma of the stomach.

Thereafter the patient developed dyspnea and ascites. C-T and abdominal sonography showed bilateral pleural effusion, ascitic fluid accumulation, large cystic adrenal masses bilaterally and the presence of a large mass in the anatomical area of the uterus and the right ovary. The rest of the viscera were negative for findings.

The patient developed severe progressive dysphagia, cachexia and bilateral lower leg edema. Thereafter she lived another 15 days in a moribund condition and she died on January 2002.

## Discussion

Malignant melanoma is known to metastasize to different organs of the human body with an unusual predilection for the gastrointestinal tract. Gastrointestinal inva-

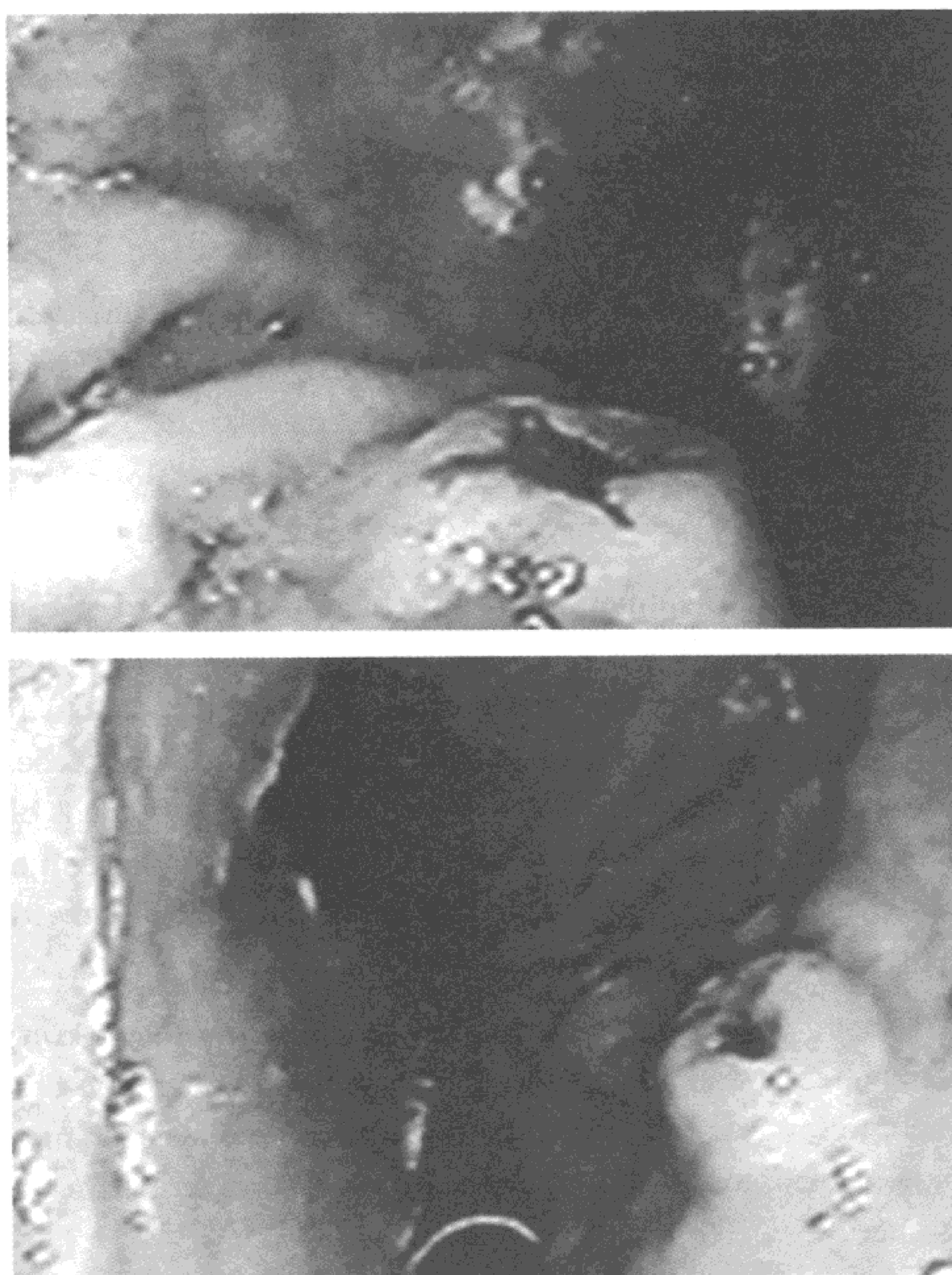
sion is a rare condition and is often associated with the invasion of other visceral organs.<sup>11</sup> The mean survival time of these patients is consistently less than a year.

The exact clinical incidence of gastrointestinal melanoma cannot be stated by any large series, but the stomach following the small bowel is the second most common site involved.<sup>2,3,8,12</sup> Symptoms include mainly gastrointestinal bleeding, abdominal pain, anorexia, nausea and vomiting, weight loss, progressive dysphagia, obstruction and occasionally acute perforation.<sup>11</sup> Melena in a melanoma patient seems to be a cardinal symptom for gastrointestinal metastasis, even in the absence of other symptoms. In our case the patient never had melena and she did not have the other symptoms mentioned, except in the late stages of the disseminated disease. In the majority of the cases reported, the gastric involvement was a manifestation of terminal metastasis. It has also been reported that almost all the areas of the human body can be affected by melanoma metastases.<sup>1</sup>

Many of the previous reports on the gastric spread were based on the radiological features of the metastases and barium meal seemed to be the most important examination to detect them. Recently endoscopy has been shown to be a more reliable diagnostic tool. It permits exact morphologic evaluation and direct biopsy for pathological diagnosis of the disease. Moreover by endoscopic follow-up it is possible to monitor the course of metastases and to evaluate the results of the treatment.

The endoscopic classification of the gastric metastases comprises three main morphological types: (a) melanotic nodules, often ulcerated at the tip; this is the most frequent endoscopic feature, (b) submucosal tumor masses, melanotic or not, elevated and ulcerated at the apex; this is the typical aspect of "bull's eye" lesions and (c) mass lesions with varying incidence of necrosis and melanosis. Additionally gastric metastases may appear even as a simple ulcer.<sup>10,12</sup> Concerning the anatomical site of the gastric metastases, the majority of them are reported to occur in the body and the fundus, most often at the greater curvature, with the lesser curvature lesions being uncommon.<sup>11</sup> In our patient the endoscopic picture of the gastric lesion belonged to the submucosal, non melanotic, ulcerated in the apex mass type. The lesion was located in the greater curvature of the body of the stomach. The pathological evaluation could not confirm the primary or metastatic nature of the melanoma lesion.

The distribution of cutaneous and/or subcutaneous metastases in melanoma patients follows certain pathways. These metastases result from either lymphatic or



**Figure 1.** Two endoscopic views of the same gastric mass. Submucosal, non melanotic and ulcerated at the apex lesion.

vascular spread.<sup>12</sup> The vascular route is more common in diffuse melanoma and is the result of a "shower" of melanoma cells into the blood stream. In our patient the initial presentation of the disease with inguinal lymph node metastases is an unusual situation. A possible primary gastric melanoma could not explain this type of lymphatic spread. A thorough investigation of the external genitalia, the lower legs and the whole body of the patient did not show any other primary lesion. Even the case of a melanoma which regressed was excluded from the clinical history of the patient.

The first step in evaluating a patient with metastatic melanoma from an unknown primary site is to search the skin carefully for a possible primary lesion. The next step is a careful physical examination, including ophthalmoscopy, to detect evidence of visceral or disseminated metastases. The disappearance of a primary lesion through the process of spontaneous regression and later discovery of metastatic melanoma are not uncommon and should also be detected. Ten to 20% of these patients describe having had a mole on the skin within the lymphatic drainage area of the nodal metastasis. Typically this lesion was noticed within the proceeding 1–3 years, when it became raised, itched, bled, or was subjected to minor injury and then disappeared leaving only a pale scar. It is possible that the immune response directed against melanoma antigens that caused the destruction of the primary melanoma might be responsible for the long term survival observed in some of the reported cases.<sup>13</sup> Melanoma is among the best examples of a human tumor in which the immune system plays a major role. It accounts for an unusually high percentage of the well-documented cases of all cancer regressions.<sup>14</sup>

In our patient the thorough physical examination, to detect evidence of a regressed lesion or a primary melanoma was negative. Equally, the secondary origin of the gastric melanoma from the inguinal region remained unexplained. Thus, we concluded that this unusual clinical picture was compatible with a primary melanoma of the stomach.

Although surgical treatment has been attempted in some melanoma patients with gastrointestinal metastases, surgery seems to be of limited practical value and should be performed only in carefully selected patients, or in patients with complications. In the subgroup of patients with symptomatic metastases to the small bowel, operations are an alternative in seeking relief of the symptoms.<sup>4,10,11</sup> The poor general condition of our patient by the time of the diagnosis, complicated with other organ metastases, did not allow any surgical treatment apart from palliative pleural and ascetic fluid aspirations.

## Conclusion

Metastatic melanoma to different organs of the human body, from an unknown primary lesion, is well reported in the literature. The stomach, following the small bowel, is the second most common site involved. The primary origin of a melanoma of the stomach is extremely unlikely and could only be accepted if the absence of a primary lesion can be proved. During the last years endoscopy has been shown to be the most reliable examination for the diagnosis of gastric metastases. In addition, gastric invasion is most often associated with the invasion of other organs and the mean survival time of patients presenting with a gastric metastasis is consistently less than a year.

## References

1. Das Gupta T, Brasfield R. Metastatic melanoma: A clinico-pathological study. *Cancer* 1964, 17:1323–1339
2. Calkins WG, Hoppel CL. Malignant melanoma of the stomach. *Am J Gastroenterol* 1965, 43:150–154
3. Richter R, Panisch J, Berci G. Endoscopic findings in melanoma metastatic to the stomach. *Gastrointest Endosc* 1972, 18:172–175
4. Pector JC, Crokeart F, Lejeune F, Gerard A. Prolonged Survival after resection of a Malignant Melanoma metastatic to the stomach. *Cancer* 1988, 61:2134–2135
5. Macak J. Melanoma of the stomach: reality or fiction? *Pathologica* 1998, 90:388–390
6. Liang JT, Yu SC, Lee PH, Chang KJ, Fang CL, Lin WJ et al. Endoscopic diagnosis of malignant melanoma in the gastric cardia-report of a case without a detectable primary lesion. *Endoscope* 1995, 27:409
7. Woollons A, Derrick EK, Price ML, Darley CR. Gastrointestinal malignant melanoma. *Int J Dermatol* 1997, 36:129–131
8. Morini S, Bassini O, Colavolpe V. Malignant melanoma metastatic to the stomach: Endoscopic Diagnosis and Findings. *Endoscopy* 1980, 12:86–89
9. Mc Neer G, Das Gupta TK. Life history of melanoma. *Am J Roentgenol* 1965, 93:686–694
10. Reintgen DS, Thompson W, Garbutt J, Seigler HF. Radiological, endoscopic and surgical considerations of melanoma metastatic to the gastrointestinal tract. *Surgery* 1984, 95:635–639
11. Booth JB. Malignant melanoma of the Stomach: Report of a case presenting as an acute perforation and review of the literature. *Br J Surg* 1965, 52:262–270
12. Nelson RS, Lanza F. Malignant melanoma metastatic to the upper gastrointestinal tract. *Gastrointest Endosc* 1978, 24:156–158
13. Balch CM, Houghton AN, Sober AJ, Soong S. *Cutaneous Melanoma. Diagnosis and treatment of metastatic melanoma*. 3rd ed. Quality Medical Publishing, Inc, St. Louis Missouri, 1998:327–329
14. Mihm MC, Murphy GF, Kaufman N. *Pathology and recognition of Malignant Melanoma. Immunology of Melanoma*. Williams & Wilkins, 1988:50–53